

Heterotopic Transcatheter Tricuspid Valve Implantation

A promising technology for patients with high-risk TR.

By Omar Abdul-Jawad Altisent, MD, PhD, and Rodrigo Estévez-Loureiro, MD, PhD

Trascatheter percutaneous devices are an optimal alternative to surgery for the treatment of frail patients with severe tricuspid regurgitation (TR).¹ Different strategies/devices have been designed for this, from those that aim to act on the pathophysiologic cause of TR and repair systems that mimic surgical techniques to orthotopic percutaneous prostheses.² Early studies and observational data have shown promising results.^{3,4} Pending randomized data, some techniques are already expanding in clinical practice in the absence of valid therapeutic alternatives. However, a technique is emerging with a significant strength. Although it may have been considered an “unphysiological” technique, it is a safe technique and probably much more practical than others. It has also shown encouraging results in early observational studies and is therefore easily extendable. This technique is heterotopic caval valve implantation (CAVI).⁵ In this article, we review the rationale, indication/patient selection, anatomic considerations, and current evidence of this novel strategy.

RATIONALE OF SPECIFIC HETEROTOPIC BICAVAL STENTING

CAVI is intended to relieve right heart failure (RHF) signs and symptoms for patients affected by severe or higher-degree TR. CAVI is based on isolation of the right atrium (RA)–right ventricle (RV) system from the vena cava using a valved device.^{6,7} The objective is to reduce the regurgitant volume of TR to the body system, relieving congestive signs/symptoms at the hepatic, abdominal, renal, and peripheral levels. In the acute phase, improvement of liver and renal function

(reduction of diuretic resistance) is expected. There is also improvement of cardiac output (CO) caused by an increase of RV stroke volume in the pulmonary circulation.⁸⁻¹⁰ At a chronic phase, reducing RV overload is expected to reduce the risk of cardiac cirrhosis, promote a reversal of RV remodeling, and, ultimately, reduce tricuspid annulus dimension and TR. Clinically, this translates into an improvement of patient functional status, quality of life (QOL), exercise capacity, and, likely, hospitalization rates.^{10,11} Whether the CAVI procedure can improve life expectancy remains to be elucidated (Figure 1).

Importantly, CAVI is not designed primarily to reduce TR, although it can sometimes do so, but rather to treat the HF (ie, congestion signs) associated with severe TR. Thus, CAVI devices should be considered HF devices for patients with TR. This has implications, both at the level of patient selection (patients must present HF) as well as in the evaluation of the procedure’s efficacy, which will be based fundamentally on the clinical improvement of HF, not just on the reduction of TR.

The concept has several advantages, mainly based on avoiding entering the complex tricuspid valve anatomy. There is no contraindication based on leaflet gaps or annulus dilatation. Thus, compared to other tricuspid devices, there is a drastic reduction in anatomic and echocardiographic imaging requirements for implantation. The learning curve for operators is quite short, and the procedure is predictable and easy to plan according to CT images. Pacemakers or any type of leads do not interfere with the implantation process and are not considered a contraindication.^{5,12} In addition, CAVI also can be a rescue procedure in patients with a previ-

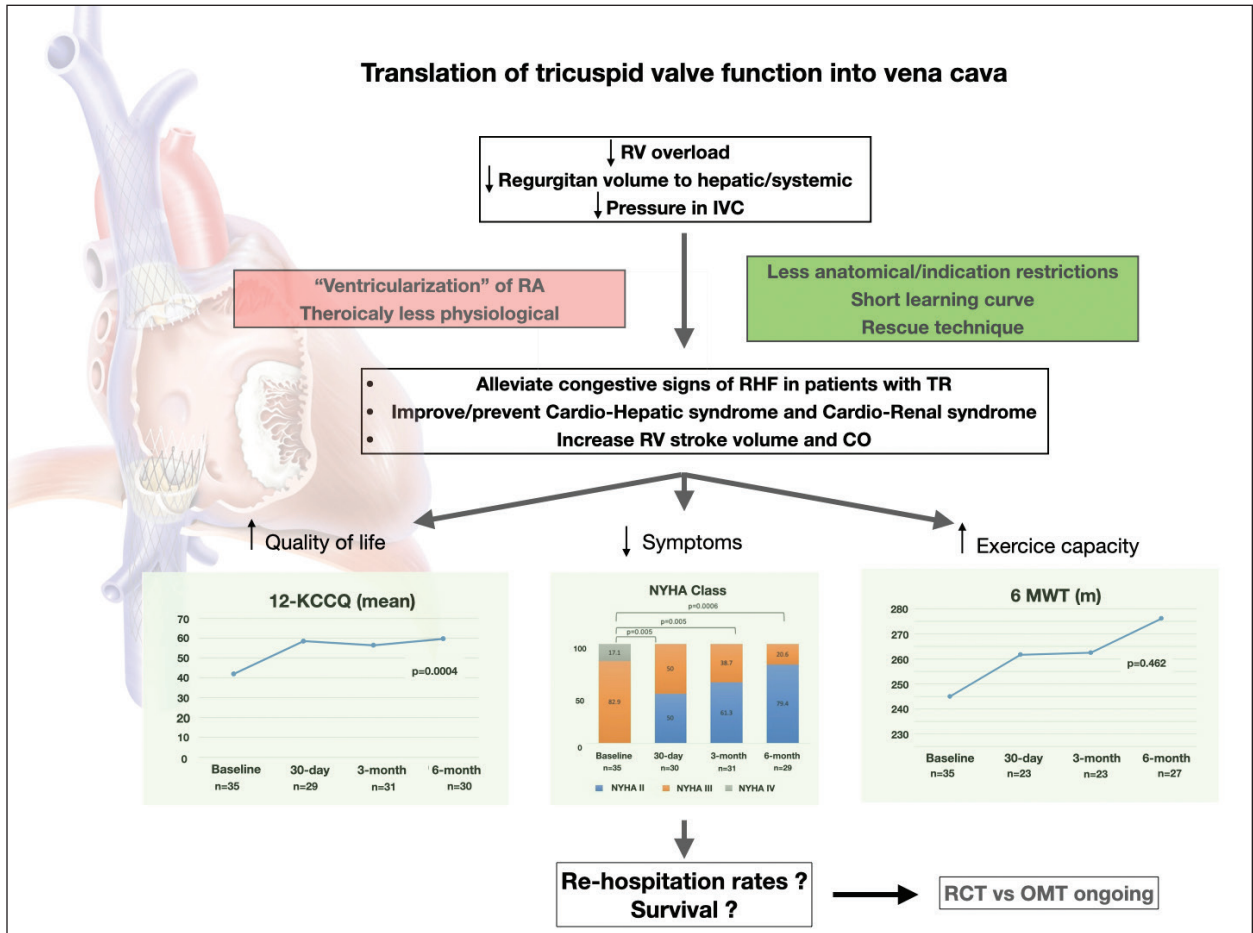


Figure 1. The bicaval concept of transferring tricuspid valve function to the junction of the vena cava–RA has clear technical advantages and some unknowns regarding the consequences of right atrial ventricularization. Nevertheless, clinical studies are showing very promising results, with an efficacy in improving HF comparable to other devices considered “more physiologic.” Abbreviations: 6 MWT, 6-minute walking test; OMT, optimal medical therapy; RCT, randomized controlled trial.

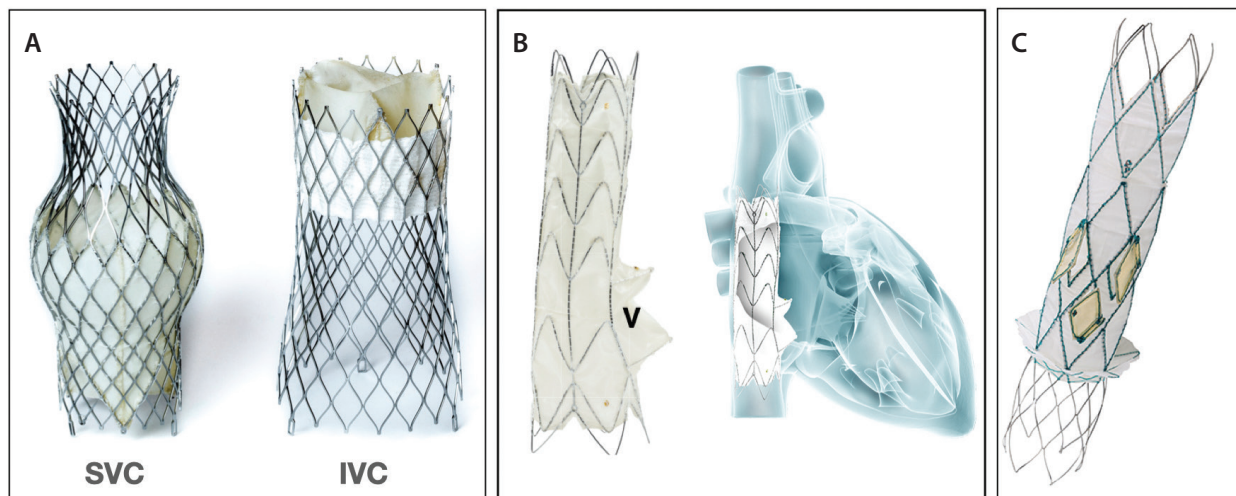
ous failure of tricuspid edge-to-edge repair or annuloplasty. Nonetheless, CAVI can be considered somewhat “unphysiologic” because we move the tricuspid apparatus function to the vena cava–RA junction, causing the “right ventricularization” of the RA.⁵ However, the reality is that in most patients in whom a CAVI procedure is performed, the atrium is already “ventricularized” and not functional, usually acting as a simple blood reservoir. Furthermore, during the first 3 months after implantation, there is an adaptation to this “new physiology” observing a reestablishment of atrial pressure values to similar preimplantation values, without any increase in the dimension of the RA.¹¹ Additionally, there is already some evidence that CO can increase significantly during the chronic phase if RV function is preserved.¹⁰

There are currently three different CAVI devices specifically designed for caval anatomy, one is focused on het-

erotic valve placement in the superior vena cava (SVC) and inferior vena cava (IVC) at the level of the atriocaval junction (TricValve system, P&F Products Features), and the other two are focused on the use of a covered stent with a valved system (Tricento system, NVT GmbH; Trillium system, Innoventric) (Figure 2).

PATIENT SELECTION

Patient selection is based on clinical, hemodynamic, and anatomic features. From a clinical perspective, and similar to other tricuspid therapies, we still need to better understand the optimal timing for CAVI, its limits, or when it may be futile or even detrimental. Perhaps it is still necessary to better understand the natural history of TR disease, which is usually multifactorial and often mixes different mechanisms (Figure 3).¹²⁻¹⁴ Table 1 shows the clinical and hemodynamic inclusion criteria for the



Images courtesy of their respective companies.

Figure 2. Current dedicated bicaval devices. The TricValve device consists of two nitinol self-expanding valvular stents designed for SVC and IVC anatomy (A). The Tricento (B) and Trillium (C) devices consist of a self-expanding covered stent frame placed into the SVC and IVC crossing through the RA to isolate the vena cava from the RA-RV system. Tricento is custom made and has a valve (v) facing the native tricuspid valve. Trillium has a skirt at its inferior part that confers complete sealing of the RA and has three openings facing the tricuspid valve. All of these systems transfer the tricuspid valve function to the vena cava–RA junction, causing the “ventricularization” of the RA.

TRICUS I and TRICUS EURO trials. These criteria may be an acceptable guide considering the positive results of these trials.¹¹ Compared to other studies of tricuspid devices, the inclusion criteria for these studies were less strict. Thus, patients in an advanced stage of the disease were probably included in these investigations. However, in the real world, we have noticed that there is a tendency to consider patients for CAVI who are at a more advanced stage of the disease than in the trials, sometimes arriving at the procedure in the final stage of the disease. The technical feasibility of the procedure and the lack of any other therapeutic alternative to alleviate patients’ signs/symptoms may be the main reasons for this.

Based on our experience, we would like to point out some considerations for patient clinical selection to avoid indications that may be futile or for which there is still no evidence of their efficacy. As explained previously, CAVI is an HF device; the patient should have RHF (congestion signs) or at least present with elevated pressures in the right chambers (tricuspid V wave > 15 mm Hg, measured by right heart catheterization) to be considered for the intervention. To date, we have no data regarding the efficacy of CAVI to prevent HF in patients without any congestive sign or symptoms (Figure 3). Obviously, severe pulmonary hypertension is an absolute contraindication. Special caution should be taken in patients with advanced renal failure (estimated glomerular filtration rate, < 20 mL/min), especially if accompanied by severe RV dysfunction. In these cases, the increment of the RV

afterload after CAVI may cause systemic hypotension, decreasing the pressure gradient at the renal glomeruli, causing a renal tamponade and precipitating the need for dialysis. In contrast, we have had good experience in patients with moderate RV dysfunction if renal function is still preserved (Figure 3).

From an anatomic perspective, venous CT scanning is essential for patient selection, sizing, and procedural planning. For example, the TricValve system covers almost all types of vena cava anatomies/sizings using the current prosthesis sizes available: three different sizes for the SVC (25, 29, and 31 mm) and four for the IVC (31, 35, 41, and 45 mm). Thus, most patients potentially can be treated with this system from an anatomic perspective. However, accurate implantation technique is important for avoiding any complications or device migration during the procedure.¹⁵ Technical details for implantation have been described elsewhere.⁵

OUTCOMES AFTER HETEROTOPIC VALVE IMPLANTATION

First investigations in experimental models of TR showed that the implantation of valved nitinol stents in both caval systems (superior and inferior) reduced pressures in the IVC and increased CO, providing that preloading of RV was increased with preserved function of the RV.⁸ First-in-human experiences involved the implantation of nondedicated devices in the IVC because a specific design for the anatomy of the vena

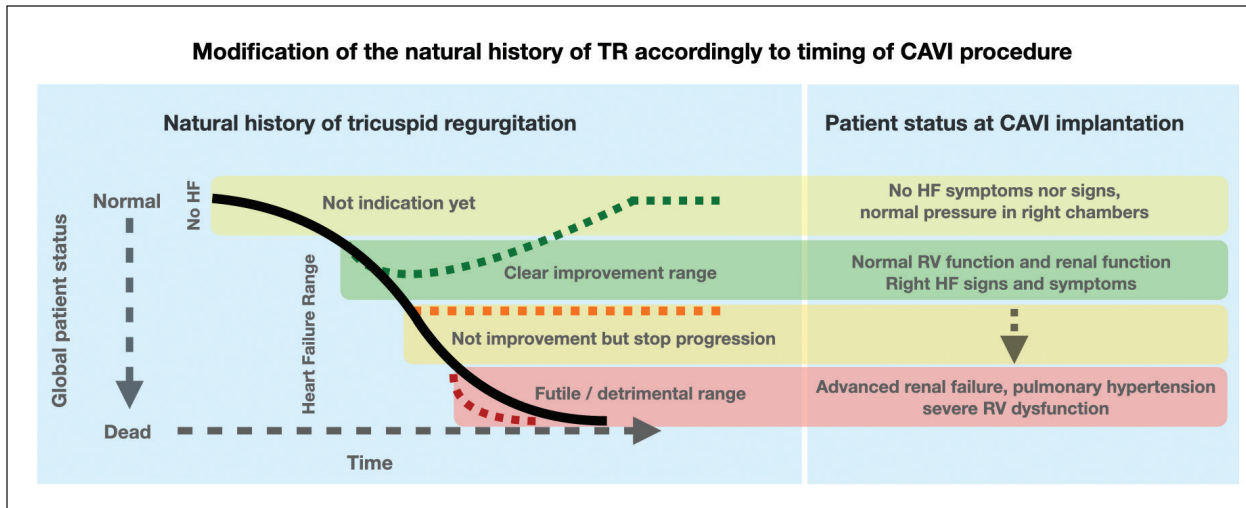


Figure 3. Theoretical model of the modification of the natural history of TR (black line) according to the CAVI procedure (dashed lines). There are still no data on the indication of CAVI in patients without HF (early stages of the disease). The best timing for CAVI is probably when the patient develops HF and renal function or RV function are still preserved (green dashed line). We still need to better understand the limits of CAVI indications, specifically until when we are able to stop the progression of the disease (orange dashed line). Conversely, if the patient has severe pulmonary hypertension or advanced renal failure with RV dysfunction, the CAVI procedure may be useless or even detrimental (red dashed line).

cava was not available and investigators feared device migration. Despite this limitation, clinical improvement was achieved in patients who were at prohibitive surgical risk.^{16,17} The largest early CAVI study was reported by Lauten et al in 2018.¹⁶ The authors included 25 patients mainly treated with a single IVC valve, using mostly non-dedicated devices but also including some of the first TricValve implants (n = 6). The authors demonstrated a high procedural success rate (92%) and clinical improvement in the majority of patients after a significant decrease in IVC pressures. However, there were two cases of valve embolization/migration, and the in-hospital mortality rate was 16%, underscoring the necessity for devices specifically designed for the anatomy of the IVC.

Dedicated devices present the advantage of allowing the implantation of valves in the SVC and IVC with high technical success and minimizing the risk of valve migration. The Tricento device is a dedicated CAVI system that consists of a stent graft that extends from the IVC to the SVC, presenting a lateral bicuspid valve that allows flow into the RA (Figure 2B).¹⁸ Clinical experience with this system has been reported recently.^{7,19} In the early experience published by Wild et al,¹⁹ 21 high-risk patients with advanced RHF symptoms underwent device implantation. Procedural success was 100%, and no in-hospital mortality was recorded. The device was associated with a significant functional improvement (65% in New York Heart Association [NYHA] functional class II at a median follow-up of 61 days) and with low

procedural adverse events. A small subgroup with cardiac MR before and after device implantation showed a degree of inverse remodeling. Similar results were reported by Cruz-González et al⁷ in which six patients were treated with the system. At 1-year follow-up, all patients experienced functional class improvement and a trend toward a reduction in the grade of TR. Although initial results have been promising, the device is custom made and presents a significant amount of exclusion features, making it less generalizable. Likewise, the development of cases of stent fractures has led to the redesign of the stent frame.

The Trillium device consists of a stent graft connecting the SVC to the IVC but differently from the Tricento. It presents three openings at the level of the RA, allowing blood to flow into the right heart chambers, and has a skirt designed to seal the bottom of the RA to enhance the avoidance of backflow into the liver (Figure 2C). There have been cases reported with initial good outcomes, and a CE Mark study is underway (NCT04289870).

TRICVALVE: THE TRICUS EURO STUDY

The TricValve system is made of two self-expanding valves specifically designed for the SVC and IVC (Figure 2A). Both devices are premounted in a 27.5-F delivery system. Caval anchoring is based on stent design, radial force, and the degree of oversizing. Although some initial experience with the device was

TABLE 1. MAIN CLINICAL AND HEMODYNAMIC ELIGIBILITY CRITERIA FOR THE TRICUS STUDY AND TRICUS EURO

Clinical	Hemodynamic
• NYHA functional class \geq III	• V wave in IVC and SVC \geq 25 mm Hg (optimized medical treatment)
• LVEF \geq 40%	• TAPSE \geq 14 mm Hg
• 6MWT \geq 60 m	• sPAP \leq 65 mm Hg
Absence of:	–
• Untreated left-sided valvular heart disease	
• Severe renal failure	
• Liver cirrhosis Child C	–
Abbreviations: 6MWT, 6-minute walking test; LVEF, ejection fraction; IVC, inferior vena cava; NYHA, New York Heart Association; sPAP, systolic pulmonary artery pressure; SVC, superior vena cava; TAPSE, tricuspid annular plane systolic excursion.	

reported, the study that led to CE Mark recently and has more closely surveilled the performance of this system is the TRICUS EURO study.¹¹ This study is also the most comprehensive evaluation of a dedicated CAVI technology. TRICUS EURO was a nonblinded, nonrandomized, single-arm, multicenter, prospective trial enrolling patients from 12 institutions in Spain and Austria. The target population was patients with symptomatic, at least severe TR despite optimized medical treatment (OMT) (symptoms and signs of RHF and NYHA class III or IV) that was demonstrated within 8 weeks before TricValve implantation, with echocardiography demonstrating significant backflow in the IVC and/or SVC and a tricuspid V wave in the right heart catheterization \geq 25 mm Hg. The primary endpoint was the assessment of changes in NYHA functional class and changes in QOL (measured using the Kansas City Cardiomyopathy Questionnaire-12 [KCCQ12] score) at 6-month post-TricValve implantation. The study counted on a core lab for echocardiography and CT scan analysis, both before the procedure and during follow-up.

Thirty-five patients (mean age, 76 ± 6.8 years; 83% women) were included in the study. All patients were in advanced functional class, mostly in NYHA class III, and accumulated a significant number of comorbidities. All patients also presented with symptoms and signs of RHF. From an echocardiographic standpoint, left ventricular function was preserved, with most cases demonstrating dilated right-sided chambers with

normal RV function. Regarding procedural outcomes, the study was associated with high procedural success (94% of cases) and no procedural mortality or strokes. No surgical conversions were reported. The most frequent adverse event was shoulder pain, likely related to IVC prosthesis compression over the phrenic nerve, accounting for 28.5% of patients.

The most interesting result is the observation of a significant improvement in NYHA functional class and QOL at 6-month follow-up after device implantation; 79.4% of patients were in class I or II at 6 months (vs 0% at baseline), and KCCQ12 punctuation increased from 42.01 ± 22.3 at baseline to 59.7 ± 23.6 at 6 months, with both results being statistically significant (Figure 2). At 6 months, mortality was 8.5% with no cardiovascular mortality reported, and the most frequent complication was major bleeding, which occurred in 17.1% of patients. RHF symptoms resolved in almost 60% of patients, allowing for a reduction of diuretic dosages. The distance covered in the 6-minute walk test was increased, although this was not statistically significant. Another interesting finding is the absence of right chamber dilatation or significant RV function deterioration in the echo analysis at 6 months—a finding that is reassuring taking into account the ventricularization of the RA. CT scan analyses at 3 months showed integrity of the leaflets and valve stents.

These promising results must be confirmed in larger registries with longer clinical and imaging follow-up to clarify which patients can benefit most from the therapy. A randomized controlled trial compared to OMT is under development. All this information will help better determine the ideal candidate for the therapy.

CONCLUSION

Heterotopic CAVI is a promising technology for patients with high-risk TR, with fewer anatomic exclusions and less complex procedures. There are several devices under study, with the TricValve having gained more widespread adoption. The TRICUS EURO study demonstrated a positive effect of the therapy in clinical outcomes and QOL, and it represents a valid alternative for treatment in such a high-risk population with very limited options. ■

- Rodes-Cabau J, Taramasso M, O'Gara PT. Diagnosis and treatment of tricuspid valve disease: current and future perspectives. *Lancet*. 2016;388:2431-2442. doi: 10.1016/S0140-6736(16)00740-6
- Asmarats L, Puri R, Latib A, et al. Transcatheter tricuspid valve interventions: landscape, challenges, and future directions. *J Am Coll Cardiol*. 2018;71:2935-2956. doi: 10.1016/j.jacc.2018.04.031
- Nickenig G, Weber M, Lurz P, et al. Transcatheter edge-to-edge repair for reduction of tricuspid regurgitation: 6-month outcomes of the TRILUMINATE single-arm study. *Lancet*. 2019;394:2002-2011. doi: 10.1016/S0140-6736(19)32600-5

(Continued on page 66)

(Continued from page 60)

4. Solano-López J, Zamorano JL, García-Martín A, et al. Mid-term outcomes of percutaneous tricuspid annuloplasty with the Cardioband device. *Rev Esp Cardiol (Engl Ed)*. 2021;74:888-890. doi: 10.1016/j.rec.2021.03.013
5. Abdul-Jawad Altisent O, Benetis R, Rumbinaite E, et al. Caval valve implantation (CAVI): an emerging therapy for treating severe tricuspid regurgitation. *J Clin Med*. 2021;10:4601. doi: 10.3390/jcm10194601
6. Figulla HR, Kiss K, Lauten A. Transcatheter interventions for tricuspid regurgitation-heterotopic technology: TricValve. *EuroIntervention* J2016;12;Y116-Y118. doi: 10.4244/EIJV12SYA32
7. Cruz-González I, González-Ferreiro R, Amat-Santos IJ, et al. TRICENTO transcatheter heart valve for severe tricuspid regurgitation. Initial experience and mid-term follow-up. *Rev Esp Cardiol (Engl Ed)*. 2021;74:351-354. doi: 10.1016/j.rec.2020.09.016
8. Lauten A, Figulla HR, Willich C, et al. Percutaneous caval stent valve implantation: investigation of an interventional approach for treatment of tricuspid regurgitation. *Eur Heart J*. 2009;31:1274-1281. doi: 10.1093/eurheartj/ehp474
9. Abdul-Jawad Altisent O, Codina P, Puri R, Bayés-Genís A. Transcatheter bi-caval valve implantation (CAVI) significantly improves cardiac output: mechanistic insights following CardioMEMS® and TricValve® implantation. *Clin Res Cardiol*. 2022;111:966-968. doi: 10.1007/s00392-022-02029-8
10. Estévez-Loureiro R, Sánchez-Recalde A, Amat-Santos IJ, et al. 6-month outcomes of the TricValve system in patients with tricuspid regurgitation: the TRICUS EURO study. *JACC Cardiovasc Interv*. 2022;15:1366-1377. doi: 10.1016/j.jcin.2022.05.022
11. Aparisi Á, Amat-Santos IJ, Serrador A, et al. Current clinical outcomes of tricuspid regurgitation and initial experience with the TricValve system in Spain. *Rev Esp Cardiol (Engl Ed)*. 2020;73:853-854. doi: 10.1016/j.rec.2020.03.001
12. Taramasso M, Gavazzoni M, Pozzoli A, et al. Tricuspid regurgitation: predicting the need for intervention, procedural success, and recurrence of disease. *JACC Cardiovasc Imaging*. 2019;12:605-621. doi: 10.1016/j.jcmg.2018.11.034
13. Dreyfus GD, Martin RP, Chan KM, et al. Functional tricuspid regurgitation: a need to revise our understanding. *J Am Coll Cardiol*. 2015;65:2331-2336. doi: 10.1016/j.jacc.2015.04.011
14. Dreyfus J, Audureau E, Bohbot Y, et al. TRI-SCORE: a new risk score for in-hospital mortality prediction after isolated tricuspid valve surgery. *Eur Heart J*. 2022;43:654-662. doi: 10.1093/eurheartj/ehab679
15. Kültürsay B, Bingöl G, Güven B, et al. TricValve pop-out: management of transcatheter caval valve migration. *Anatol J Cardiol*. 2022;26:414-418. doi: 10.5152/AnatolJCardiol.2021.1247
16. Lauten A, Figulla HR, Unbehaun A, et al. Interventional treatment of severe tricuspid regurgitation. *Circ Cardiovasc Interv*. 2018;11:e006061 doi: 10.1161/CIRCINTERVENTIONS.117.006061
17. Dreger H, Mattig I, Hewing B, et al. Treatment of severe TRicuspid regurgitation in patients with advanced heart failure with CAval vein implantation of the Edwards Sapien XT VALVe (TRICAVAL): a randomised controlled trial. *EuroIntervention*. 2020;15:1506-1513. doi: 10.4244/EIJ-D-19-00901
18. Toggweiler S, De Boeck B, Brinkert M, et al. First-in-man implantation of the Tricento transcatheter heart valve for the treatment of severe tricuspid regurgitation. *EuroIntervention*. 2018;14:758-761. doi: 10.4244/EIJ-D-18-00440
19. Wild MG, Lubos E, Cruz-Gonzalez I, et al. Early clinical experience with the TRICENTO bicaval valved stent for treatment of symptomatic severe tricuspid regurgitation: a multicenter registry. *Circ Cardiovasc Interv*. 2022;15:e011302. doi: 10.1161/CIRCINTERVENTIONS.121.011302

Omar Abdul-Jawad Altisent, MD, PhD

ICCV, Hospital Clinic de Barcelona

Barcelona, Spain

*Disclosures: Received proctor fees from P&F Products Features.***Rodrigo Estévez-Loureiro, MD, PhD**

Interventional Cardiology Unit

Division of Cardiology

Hospital Álvaro-Cunqueiro

Vigo, Spain

roiestevez@hotmail.com;

rodrigo.estevez.loureiro@sergas.es

Disclosures: None.